



Article Type: Research Article

Received: 30/06/2020

Published: 14/07/2020

DOI: 10.46718/JBGSR.2020.01.000067

# Analysis of the Effectiveness of Conservative Treatment of Patients with Low-Back Pain by Regenerative Injecting Therapy

Martsyniak SM<sup>1</sup>, Slobodyanyuk NP<sup>1</sup>, Hubenko VP<sup>2</sup>, Telepenko HV<sup>1</sup> \*<sup>1</sup> State Institution "Institute of Traumatology and Orthopaedics of the NAMS of Ukraine", Kyiv, Ukraine<sup>2</sup> Shupyk National Medical Academy of Postgraduate Education

\*Corresponding author: Telepenko HV, Intern, State Institution "Institute of Traumatology and Orthopaedics of the NAMS of Ukraine", Kyiv, Ukraine

## Abstract

**Background:** An open-label clinical study was conducted to evaluate the efficacy and tolerability of regenerative injecting therapy. The purpose of the study: to assess the effectiveness of regenerative injecting therapy, as well as to analyze the degree of effectiveness of this method in patients with vertebrogenic pain syndromes.

**Materials and Methods:** The study involved 30 patients of both sexes aged 20 to 60 years with vertebrogenic pain syndromes: chronic lumbalgia, vertebrogenic syndrome due to spondyloarthrosis, radiculopathy. General clinical (clinical and neurological, using scales for pain assessment), instrumental (X-ray, magnetic resonance imaging, ultrasound), laboratory methods were used.

**Results:** The results of the study of regenerative injecting therapy showed a statistical improvement in the patients' condition. According to the long-term results, conservative treatment (regenerative injecting therapy) has been shown to improve physical well-being, increase the ability to work, general perception of the quality of life of patients, and also had good tolerability.

**Keywords:** Lumbalgia; Protrusion; Spondyloarthrosis; Regenerative injecting therapy

## Introduction

The problem of pain in the lower back is the most common reason for patients to see a neurologist and orthopedist-traumatologist. In Ukraine, the number of patients with this pathology is constantly growing. Thus, in 2015, 3,249,396 cases of musculoskeletal diseases were registered in the adult population, which is 36,916 (1.15%) more than in 2014. The incidence increased by 1.67% and is 1102.44 cases per 10,000 adult population [1-3]. In the world, this pathology predominates among the diseases that cause temporary disability, and in the EU is the second most frequent cause visiting the doctor [4,5]. Lower back pain is the most common cause of disability. At the same time, between the ages of 30 and 45, only 40% of patients seek medical help.

The importance and urgency of this problem is evidenced by the significant proportion of adverse effects of this symptom complex, high prevalence and unsatisfactory results in some patients, despite the existence of modern effective therapy. Polymorphism of symptoms of degenerative diseases of the spine is due, firstly, the pathology of a large number of structural and functional elements of the vertebromotor segment [6,7]; secondly, the multiplicity of conflict options of the elements of the vertebromotor segment and the elements of the spinal

cord, blood vessels [8-10]; third, somatovegetative connections of spinal segments and elements of the spinal cord with other organs and systems of the body. The causes of radiculopathy are edema and ischemic changes in the surrounding tissues [5].

Today, the possibility of reducing the duration of rehabilitation due to early activation of the patient is increasing. However, in recent decades, the direction of minimally invasive or interventional methods of treatment, which are currently allocated in a separate direction. A distinctive feature of usage of platelet-rich plasma (PRP-therapy) is its physiology, absence of allergic manifestations, the ability to influence various links in the pathogenesis of the disease, and the organic combination with other therapeutic factors [11]. Nowadays, PRP therapy is one of the successful areas of tissue engineering and cell therapy in medicine. When tissue is damaged, platelets play an important role in tissue healing and regeneration by releasing growth factors that have a positive effect on bone and cartilage regeneration. One of the main mechanisms of regeneration is to increase blood supply to tissues by stimulating angiogenesis [12].

## Objective

To evaluate the results of treatment of pain caused by protrusions and spondyloarthritis, using the method of application of platelet-enriched plasma.

## Materials and Methods

The clinical study was conducted with 30 patients of both sexes aged 20 to 60 years with vertebrogenic pain syndrome, who were on outpatient treatment in the outpatient department of the Institute of Traumatology and Orthopedics [13]. Among those explored were 18 (60%) women and 12 men (40%). The mean age of patients was  $43.8 \pm 4.2$  years. All patients received comprehensive conservative treatment before going to the clinic: nonsteroidal anti-inflammatory drugs (NSAIDs) - 30 (100%) patients, gabapentin - 18 (52.6%), physiotherapy - 11 (40.6%), therapeutic gymnastics - 15 (50%), paravertebral injection of corticosteroids - 8 (22.2%).

All patients got injections of platelet-enriched plasma in facet joints at the level of L1-L2, L2-L3, L4-L5, L5-S1 of the spine under the control of ultrasound (US).

During treatment, all patients were examined by general clinical methods:

1. Objective examination of the patient (measurement of heart rate, blood pressure, examination of the skin and mucous membranes);
2. Registration of subjective complaints of the patient;
3. Neurological examination.

Instrumental examination methods were used: radiography, magnetic resonance imaging (MRI), ultrasound and electromyography of the lower extremities. Laboratory examination was also performed: general blood test (erythrocytes, hemoglobin, color index, platelets, leukocytes, erythrocyte sedimentation rate). The main complaint of patients was low back pain. MRI results in all patients confirmed intervertebral disc protrusion and spondyloarthritis of the facet joints of the lumbar spine. Quantitative and qualitative assessment of the pain syndrome was performed using a visual analog scale (VAS) of pain. Patients were assessed before the procedure and on days 7, 13, 21, and 27 of the study. Criteria for inclusion in the study: patients with pain on the background of protrusions, deforming osteoarthritis of facet joints with neurological symptoms, the ineffectiveness of conservative treatment. Systematic usage of NSAIDs for reducing pain [14,15].

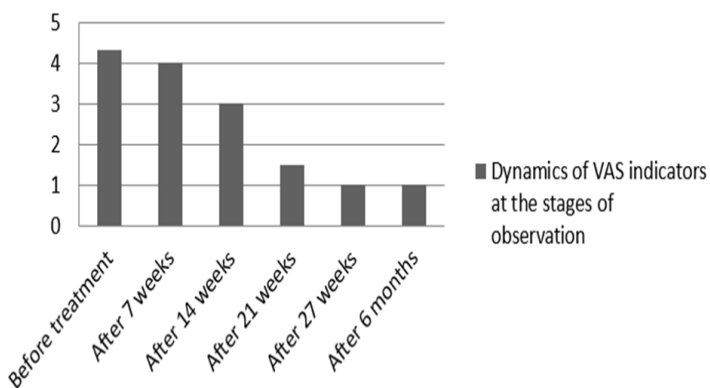
Patients were fasted 40 ml of blood from the ulnar vein, after which the blood was evenly distributed in 2 sterile vacutainers with sodium citrate solution and centrifuged for 8 min (speed - 1800 rpm) with an acceleration of 460 on the device CENTRSFUGE CM-6M. After centrifugation of whole blood and its subsequent layer stratification in sterile conditions with a sterile syringe, a layer of plasma rich in growth factors was taken, determining the number of erythrocytes, leukocytes and whole blood platelets and in optimal plasma after centrifugation. On average, after centrifugation, a growth factor-rich plasma of 5.0 ml was obtained and under control of ultrasound diagnostics (Philips HD-11 XE №USD0874946, 2009), using a multifrequency cone sensor the active substance was injected paravertebrally into the facet joints up to four times every 7 days. The study was performed on the affected areas, compared with healthy ones.

Statistical analysis of the obtained results: analysis of categorized data was performed using the following criteria: Q-criterion of Cochren (to establish the effectiveness of treatment in the dynamics); separate pairwise comparisons in the middle of the groups were performed using the McNemar test, the analysis

of scores was performed using statistical Friedman criteria (single nonparametric analysis of variance).

## Results and Discussion

At the initial examination of vertebral neurological signs most often encountered changes were in the lumbar spine due to deforming osteoarthritis of the joints at the level of L2-L3, L3-L4, L4-L5, L5-S1 in 30 patients (100%). Of these, 7 patients (23.3%), in addition to spondyloarthritis of their joints, had manifestations of radiculopathy L4, L5, S1 level on the background of protrusions of the intervertebral discs, and 5 patients (16.7%) - with pain caused by spondyloarthritis, with severe reflex-muscular-tonic manifestations (piriformis syndrome). The acute course of the disease was noted in 6 patients (20%), chronic - in 24 (80%). All patients radiologically revealed degenerative-dystrophic changes of the lumbar spine, MRI - spondylosis, spondyloarthritis, and protrusion of intervertebral discs. Irritation of the roots at the level of L3, L4, S1 was confirmed by electroneuromyography of the lower extremities. On objective neurological examination, all patients were diagnosed with pain in the lumbar spine with irradiation to the lower extremities, paresthesias in the relevant dermatomes, reduced knee, Achilles and plantar reflexes (**Figure 1**).



**Figure 1:** Dynamics of VAS Indicators at the Stages of Observation.

Vertebrogenic syndrome on the background of deforming arthrosis of the joints of the spine in 30 patients (100%) was manifested by severe localized pain, accompanied by immobility and stiffness of the affected spine, increased fatigue and greatly increased with a change in a static position (especially in the morning or after significantly decreased or disappeared after movements. Radical syndrome (radiculopathy) was observed in 7 patients (23.3%) and was characterized by radiating pain in the corresponding dermatome, a feeling of paresthesia, decreased reflexes (knee, plantar, Achilles) in 2 patients, muscle malnutrition. Piriformis syndrome was manifested by pain in the lumbosacral spine - in 5 patients (16.7%), on the outer thighs, anterior tibia, tension of the femoral adductors and pain on palpation and stretching in them (**Table 1**).

Complete reduction of pain after treatment was observed in 18 patients (60%), and in most (12 patients, 40%) it was registered by the 14th day of treatment, in 4 patients (16.4%) - by the 21st day of therapy and only in 2 patients (6.6%) - up to the 27th day of treatment. Of the 8 patients (26.7%) who received a 27-day course of treatment, only 2 patients (6.6%) showed complete reduction of pain, and 2 patients (6.6%) had minor pain, which

**Table 1:** The analysis of subjective and objective neurological symptoms allowed us to identify the leading clinical syndromes.

	Duration of treatments (days)				The Degree of reduction of pain (Number of Patients)		
	7	14	21	27	Complete Reduction	Significant improvement	Slight improvement
Reflex Syndrome	7	14	21	27	Complete Reduction	Significant improvement	Slight improvement
Vertebrogenic Syndrome on the background of spondyloarthritis	18	18	6	4	7	–	–
Radical Syndrome (radiculopathy)	7	7	6	2	3	1	1
Piriformis Syndrome	5	2	2	–	8	9	1
Total	30	27	14	6	18	10	2

was intermittent and appeared during the day. These were patients with a long history of pain (more than six months), mostly women, and with more distinct changes in spinal radiography and MRI.

Before treatment, 19 patients (63.3%) rated the severity of pain for VAS as 6-8 cm, 9 patients (30%) - 8-10 cm and only 2 (6.7%) - 4-5 cm. After the treatment course, the absence of pain in the spine was noted by 17 patients, it was assessed by YOU from 2 to 3 cm - 9 patients, from 3 to 4 cm - 4 patients. Thus, a complete reduction of the pain syndrome for VAS was observed in 56.7% of patients, a significant reduction - in 30%, a slight - in 13.3% of patients. According to the scale of general clinical impression, the severity of the disease was classified as "moderate changes" in 21 patients - reduction of vertebrogenic pain, restoration of knee, plantar, Achilles reflexes, and preservation of sensitivity in the relevant dermatomes. Significant changes - in 7 patients, as mild manifestations - in 2 patients in the form of malnutrition of the muscles of the thigh, leg, hypostasis in the relevant dermatomes. During the study, under the influence of regenerative injection therapy, patients significantly reduced complaints, there was a positive quantitative dynamic of subjective and objective neurological symptoms. Significant improvement - in 60% of patients, moderate improvement - in 33.3% of patients. Survey and neurological examination of patients during treatment did not reveal any additional complaints, unexpected side effects, complications or allergic reactions.

#### Conclusion

1. The method of regenerative injection technology is effective in the treatment of pain in deforming arthrosis of the lumbar spine and protrusions of the intervertebral discs. However, it is not universal and cannot slow the progression of the underlying disease, so it is recommended to be used with other treatments.
2. Two or three injections of the drug in the early treatment of deforming arthrosis of the lumbar spine inhibits the development of degenerative-dystrophic process, which, in turn, has a positive effect on the dynamics of pain.
3. The procedure of regenerative injections requires further study in a significant number of patients with long-term follow-up.

#### Conflict of Interest

The authors declare the absence of a conflict of interest in the preparation of this article.

#### References

1. Koes BW, van Tulder MW, Thomas S (2006) Diagnosis and treatment low back pain. *BMJ*. 332(7555): 1430-1434.
2. Podchufarova EV, Jahno NN (2013) *Bol' v spine: rukovodstvo [Back pain: a guide]*. 2nd ed. Moscow: GEOTAR, pp. 368.
3. Dohan Ehrenfest DM, Rasmusson L, Albrektsson T (2009) Classification of platelet concentrates: from pure platelet-rich plasma (P-PRP) to leucocyte and platelet rich fibrin (L-PRF). *Trends Biotechnol.* 27(3): 158-67.
4. Nikiforov AS, Avakjan GN, Mendel' OI (2015) *Nevrologicheskie oslozhneniya osteohondroza pozvonochnika [Neurological complications of spinal osteochondrosis]*. 2nd ed. Moscow: GEOTAR, pp. 272.
5. Klimenko AV, Golovchenko Iul, Kalishchuk-Slobodin TN (2007) Features of management of patients with chronic vertebral pain of lumbosacral localization. *Zdorov'ja Ukrainy*. 159: 38-39.
6. Turbina LG. Dorsalgia. *Lechaschii Vrach.* (2007) 155:1216.
7. Van Middelkoop M, Rubinstein SM, Kuijpers T (2011) A systematic review on the effectiveness of physical and rehabilitation interventions for chronic non-specific low back pain. *Eur Spine J* 20(1): 19-39.
8. Kuznetsov VF (2000) *Spravochnik po vertebronevrologii: klinika, diagnostika [Handbook of vertebral neurology: clinic, diagnosis]*. Minsk; Belarus', pp. 351.
9. Devreaux MW (2004) Low back pain. *Prim Care*. 2004 Mar 31(1): 33-51.
10. Frechette JP, Martineau I, Gagnon G (2005) Platelet-rich plasmas: growth factor content and roles in wound healing. *J Dent Res*. 84(5): 434-439.
11. Everts PA, van Zundert A, Schönberger JP, Devilee RJ, Knape JT (2008) What do we use: platelet-rich plasma or platelet-leukocyte gel. *J Biomed Mater Res A* 85(4): 1135-1136.
12. Bova AA (2008) Modern approaches to the problem of pain in the lower back. *Meditsinskie novosti* 1: 36-40.
13. Nikiforov AS, Mendel' OI (2006) Osteochondrosis and spondyloarthritis of the spine as a manifestation of a single degenerative process. *Modern approaches to treatment*. *RMJ* 14(23): 1708-1713.

- 
14. Morozova OG (2007) Acute back pain: approaches to therapy. Zdorov'ja Ukrai'ny. Nevrologija, Psihijatrija, Psihoterapija 6(1): 22-23.
15. El-Sharkawy H, Kantarci A, Deady J (2007) Plateletrich plasma: growth factors and pro and anti-inammatory properties. J Periodontol 78(4): 661-669.

\*Corresponding author: Telepenko HV, Email: telepenko1505@gmail.com

Next Submission with BGSR follows:

- Rapid Peer Review
- Reprints for Original Copy
- E-Prints Availability
- Below URL for auxiliary Submission Link: <https://biogenericpublishers.com/submit-manuscript/>

---

**Citation:** Telepenko HV, Analysis of the Effectiveness of Conservative Treatment of Patients with Low-Back Pain by Regenerative Injecting Therapy. Op Acc J Bio Sci & Res 3(2)-2020.

**DOI:** 10.46718/JBGSR.2020.01.000067